

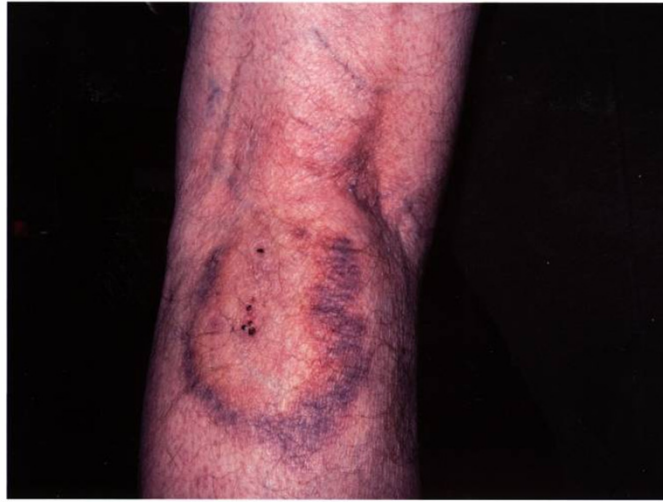LYME

A disease that ticks
all the right boxes

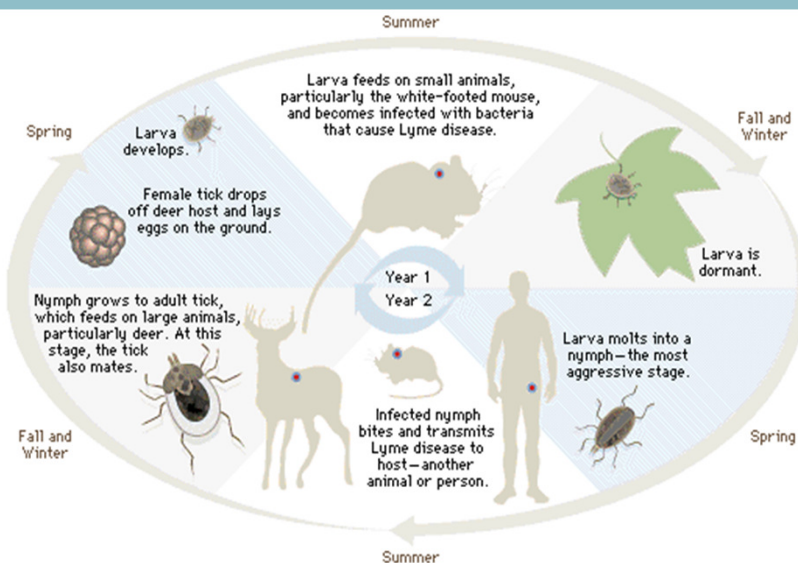
From left: deer ticks (nymph, female, male)
and female dog tick on a paper clip



Patient: photographed 22 May 2005



Lyme Disease Life Cycle



Available from: http://encarta.msn.com/media_461520246/Lyme_Disease_Life-Cycle.html

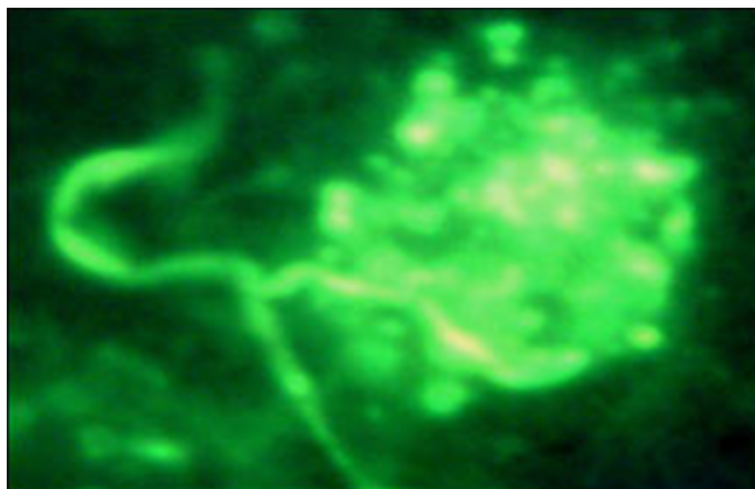
Ixodes scapularis mating



(Thanks to Jim Occi)

Borrelia burgdorferi

Three profiles in on image; Cylinder (corkscrew), Cyst (round) and Granular (dots).



by: Alan MacDonald, MD

Lyme

1975 – Lyme, Connecticut

Cluster of cases of arthritis resembling juvenile arthritis. Children had joint pains and found to have a peculiar rash.

Lyme

From *The Times*
May 11, 2007

Walkers at risk of a menace in the undergrowth

Shirley English

Visitors to the countryside are being warned of an increased risk of contracting Lyme disease, amid a sharp rise in the tick population.

With the warm spring bringing out walkers, cyclists and riders, the Health Protection Agency is advising people to take precautions against tick bites particularly when visiting woods, heaths and moorland – and even suburban parks.

In England and Wales the number of diagnoses of Lyme disease rose to 684 last year. In Scotland reported cases have risen tenfold in a decade, last year doubling to 177.

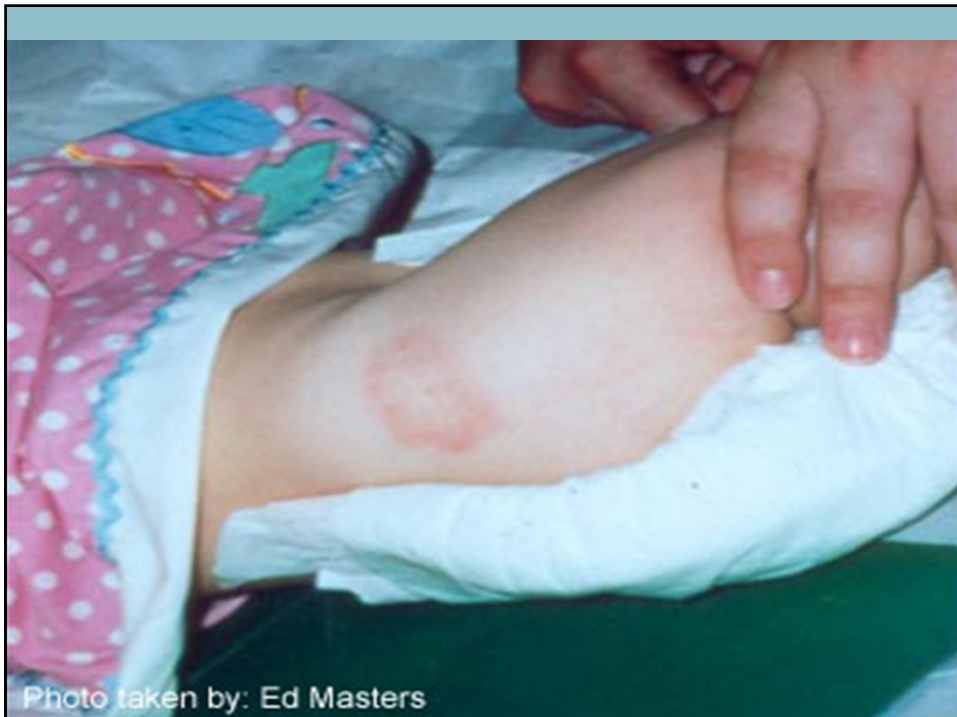The disease starts with an expanding, "bull's-eye" rash and flu-like symptoms that are treated with antibiotics. If early warning signs go undetected, the bacteria may cause complications such as arthritis, meningitis, paralysis of facial muscles, depression and memory problems.

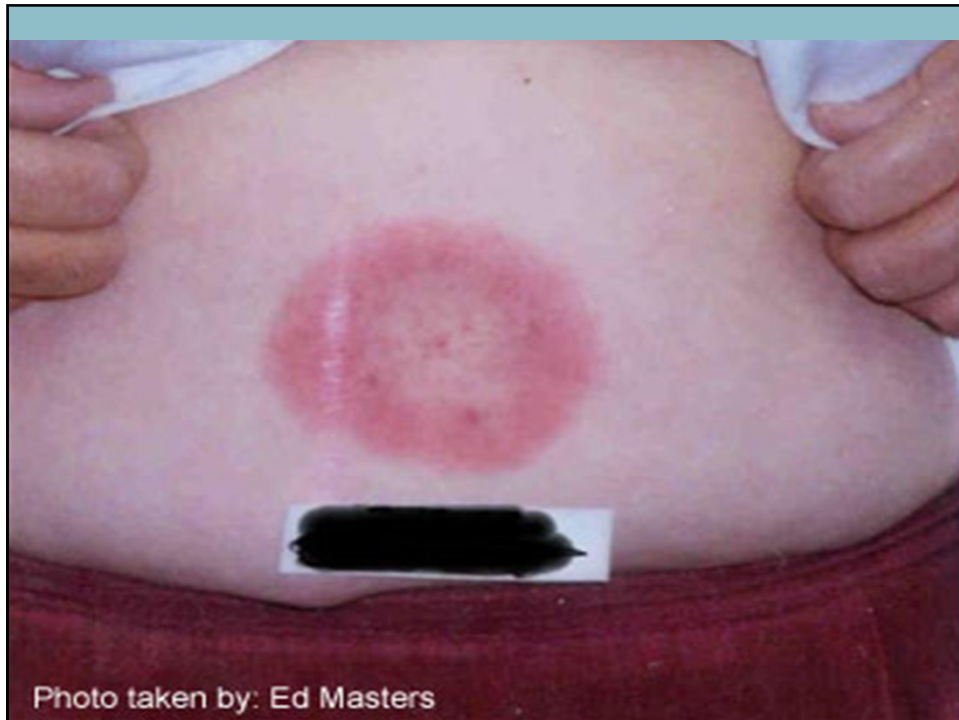**Ixodes ricinus's bite can lead to arthritis,
Meningitis or paralysis.**

Lyme

Early 1 - 4 weeks

1. Erythema migrans
2. Headache
3. Myalgia, arthritis
4. Enlarged glands





Lyme

- Musculoskeletal approx 50% migratory arthritis, polyarthritis or both
- Carditis
- Neuropathy, recently found to be small fibre with pain and altered sensation.
- Lymphadenopathy
- Ophthalmic iritis chorioiditis
- Hepatic or renal

Lyme

Late
Musculoskeletal
migratory or chronic
monoarticular arthritis
Neurologic
Cutaneous

300 medical conditions

- Arthralgia,arthritis acute oli/pauciarthritis
- Myalga PMR,MYOSITIS
- Fibromyalgia, chronic widespread pain with tender points
- CFS/Myalgic Encephalomyelitis an infectious disease involving cardiac and neurological strustures

Lyme Arthritis

Maybe only system
Large effusion inflammatory recurrent
Can last 8 years
Fibromyalgia
Tenosynovitis
Enthesitis
Periarticular pain
Test-joint fluid for PCR borrelia.

Patient: lady, age 26

96 Au pair France
S. America vaccinated typhoid yellow fever,
hepatitis. In Bolivia G.I. infection
insect bites, some neuro symptoms
97-99 Exeter, cyclic 'flu like illness
8/98 Knee injury
9/99 cycle across Kenya, then knee surgery

Patient: lady, age 26

9/00 Back pack Australia, S. America, scuba diving incident, left at sea.

Work for B.A.

11/01 unwell 'flu-like fatigue

04/02 Worse

07/03 Spoke to Dr A. Wright

Serological test negative

Patient: lady, age 26

12/03 R doxycycline

08/04 Hotel receptionist

12/04 Housebound

02/05 Dr.A.W. – amoxycillin+metronidazole

11/05 Treat coinfections

02/06 Increase in energy

04/06 Visit Dr. Burrascano levaquin etc.

Patient: lady, age 26

11/06 in Dubai

01/07 Dr. Horowitz-Plaqenil Florinef

IV glutathione

02/07 Minocycline

05/07 Breakspear-low dose immunotherapy support.

Antibiotic treatment of Lyme

Ann Rheum Dis 2005

Am. Pen v Plac study 40 pts-55% resolved

Outcome may depend on Bb species.

Ceftriaxone v plac. 60pts 48%/10% improved.

Study 16 pts refractory to antibiotics Ceft.Pr

No response for 3/12 6 pts synovectomy

2-4 year history before spont resolution